

Autofluorescence of the macula



Author: Pascal Hasler, Department of Ophthalmology, Glostrup Hospital and Kennedy Institute-National Eye Clinic, Hellerup and University Eye Hospital Basel, Switzerland

This brief review was supported by the Swiss National Science Foundation (SNSF).

The photos are made with the Heidelberg Retina-Angiography camera donated by Generalkonsul Friedrick Bøhm og datter Else Bøhms Fond.

Non-invasive methods are increasingly used to diagnose and treat various retinal diseases. Besides optical coherence tomography (OCT), one of the major methods of such analysis is through confocal laser scanning ophthalmoscope (cSLO), which can record in the autofluorescence mode a complex signal predominantly derived from autofluorescent lipofuscin granules in the retinal pigment epithelium (RPE). This method allows one to record fundus autofluorescence intensity and distribution in vivo.

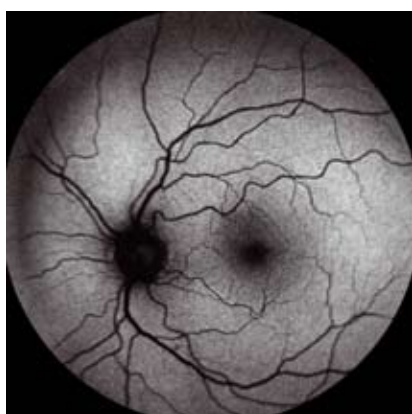

Figure 1: Fundus autofluorescence mean image of a 66-year-old male patient with normal topographic distribution of autofluorescence intensity. Absorption by retinal vessels and by macular pigment results in decreased autofluorescence signal intensity.

RPE is known to play an important role in the pathogenesis of different macular diseases such as age-related macular degeneration (AMD). These multifunctional cells consist of a single layer of hexagonal cells, the apices of which contain villous processes that envelop the outer segments of the photoreceptors. In the fovea RPE cells are taller and thinner, contain more and larger melanosomes than elsewhere in the fundus. The RPE has important functions in maintaining the integrity of the subretinal space, the space between photoreceptors and RPE cells. It is part of the outer blood-retinal barrier and pumps ions and water out of the subretinal space. Photoreceptor function is critically dependent on healthy RPE layer while RPE cells remove 'spent' photoreceptor tips in the diurnal process of photoreceptor renewal and participates in 11-cis retinol recycling. These phagocytosed outer segment tips are digested in the RPE phagolysosomal system throughout life. With time, there is an accumulation of substances, like lipofuscin pigment, which may reflect the declining ability of the RPE to handle large amount of relatively indigestible material. RPE lipofuscin normally accumulates with age, but increasing lipofuscin represents also

a common pathogenetical pathway in several retinal degenerations and dystrophies.

Lipofuscin is mainly derived from the chemically modified residues of incompletely digested photoreceptor outer segment discs. The retinoid A2E is the dominant fluorophore in the lipofuscin granules. Controversy exists with regard to effects of lipofuscin on RPE cell function and its relevance to retinal diseases, including Best disease, Stargardt disease, and age-related macular degeneration (AMD). Recent experimental findings imply that lipofuscin and certain compounds such as A2E interfere with normal RPE cell functions including lysosomal degradation and thereby release of free radicals finally leading to RPE cell death.

There are other fluorophores, which may also contribute to the fundus autofluorescent, present in various anatomic layers of the posterior pole. The basemembrane has also been shown to possess autofluorescent properties. However, the excitation and emission spectra are different, although with slight overlap, from those of lipofuscin in RPE cells. The same is the case for fluorescence appearing from choroidal components and from the sclera. Furthermore, sub-pigment-epithelial

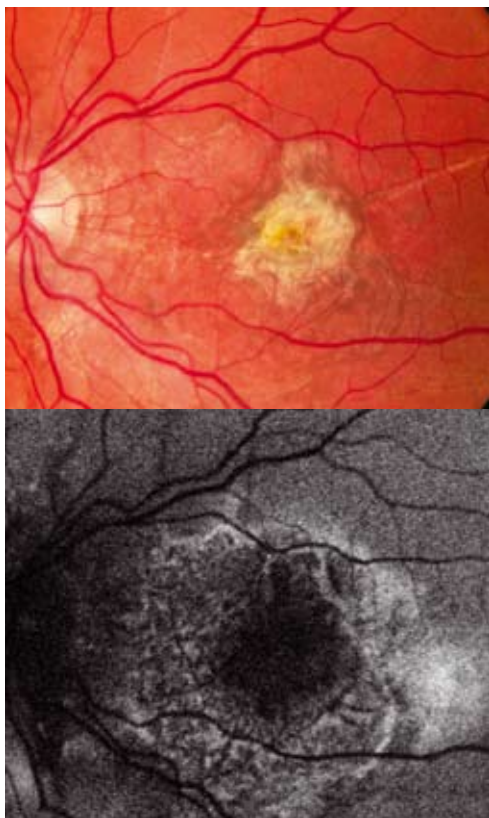


Figure 2. Fundus color and autofluorescence images of the left eye of a 49-year-old man with angioid streaks and old choroidal neovascularization scar on the left eye. Note that the region with decreased autofluorescence corresponds funduscopically with the scar area. In the junctional zone around the scar a pattern of increased autofluorescence is seen corresponding to an accumulation of lipofuscin in the RPE. These changes often precede enlargement and development of atrophic patches over time.

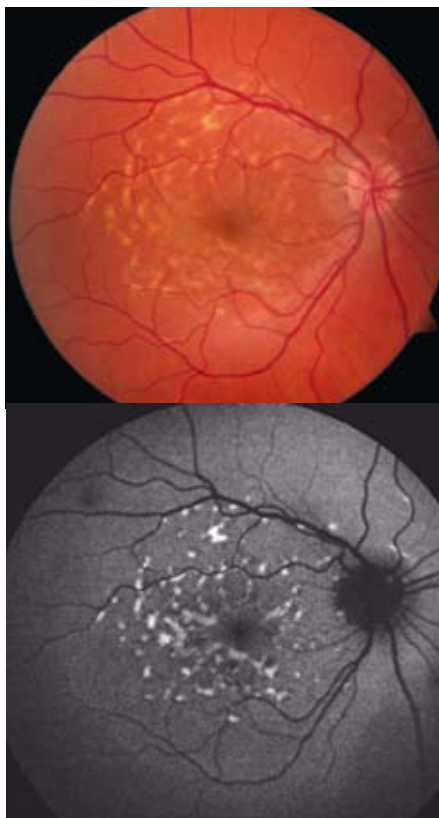


Figure 3. Fundus color and autofluorescence images of the right eye of a 42-year-old woman with Stargardt macular dystrophy. The focal flecks typically show bright, increased autofluorescence and may later fade as atrophy develops.

fluid in the presence of pigment epithelial detachments or longstanding subretinal haemorrhages may contain fluorophores that induce an increased autofluorescent signal in the wavelength ranges relevant to the method applied herein. In spite of the various retinal cells and fluids that may fluoresce, it has been shown by Delori et al. that autofluorescence is mainly derived from RPE lipofuscin.

The cSLO system allows to visualize fundus autofluorescence. Images of the fundus are recorded through a small pinhole aperture which suppresses light originating from the outside of the focal plane to enhance the image contrast compared with the nonconfocal images. For excitation at 488 nm an argon blue or optically pumped solid-state laser is used, and emission is recorded above 500 nm with a barrier filter. The im-

ages encompass the entire macular area. To enhance the quality of the image, single images can be aligned using an image analysing software leading to an amplification of the autofluorescent signal.

Absorbing structures anterior to the RPE, like macular pigment, retinal vessels, blood, hard and soft exudates are associated with a decreased autofluorescent signal. Lack of lipofuscin due to RPE atrophy leads also to decreased autofluorescence. Therefore, normal fundus autofluorescence shows a decreased amount of autofluorescence in the area of the fovea, the retinal vessels and the optic nerve head. The autofluorescence decreases also toward the periphery. The relative decrease of autofluorescence in the fovea is partly due to absorption by intraretinal yellow pigments like lutein and zeaxanthin.

Age-related macular degeneration

has become the most common cause of legal blindness in industrialized countries. Strong evidences indicate an important role of RPE in the pathogenesis of the disease. It has been shown that excessive lipofuscin accumulation precedes geographic atrophy, one of the major forms of AMD. The pattern of abnormal autofluorescence in the junctional zone of a geographic atrophy has been shown to have an impact on the progression of the disease. Drusen, a hallmark of the disease, can be associated with increased, decreased or normal autofluorescence. Whether this finding is of prognostic relevance needs to be elucidated. In a large study fundus autofluorescence changes have been classified in eyes with early and dry AMD into eight phenotypic patterns including normal, minimal changes, focal increased, patchy, linear, lace-like, reticular and speckled. Therefore, visualization of RPE changes appears to be particularly attractive to further elucidate AMD.

In macular and retinal dystrophies different changes in fundus autofluorescence have been described for further characterization of these diseases. Markedly increased autofluorescence intensity has been shown in Best disease, Stargardt macular dystrophy and adult vitelliform macular dystrophy. Fundus autofluorescence seems to be a more suitable diagnostic tool for following patients with macular and retinal dystrophies when compared with normal fundus photography.

In summary, fundus autofluorescence imaging represents one of various methods to investigate the ocular fundus, beside biomicroscopical examination, fundus photography, fluorescence and indocyanin angiography, and optical coherence tomography (OCT). This non-invasive method visualises changes of the RPE layer in vivo, while the signal is mainly derived from lipofuscin. Fundus autofluorescence imaging has and will contribute to our understanding of pathophysiology and treatment in several retinal diseases.

Referencer:

www.oftalmolog.com

- [1] Friedman DS, O'Colmain BJ, Munoz B, Tomany SC, McCarty C, de Jong PT, Nemesure B, Mitchell P, Kempen J: Prevalence of age-related macular degeneration in the United States. *Arch Ophthalmol* 2004;122:564-572.
- [2] Allikmets R, Shroyer NF, Singh N, Seddon JM, Lewis RA, Bernstein PS, Peiffer A, Zabriskie NA, Li Y, Hutchinson A, Dean M, Lupski JR, Leppert M: Mutation of the Stargardt disease gene (ABCR) in age-related macular degeneration. *Science* 1997;277:1805-1807.
- [3] Boulton M, Marshall J: Effects of increasing numbers of phagocytic inclusions on human retinal pigment epithelial cells in culture: a model for aging. *Br J Ophthalmol* 1986;70:808-815.
- [4] Feeney-Burns L, Eldred GE: The fate of the phagosome: conversion to 'age pigment' and impact in human retinal pigment epithelium. *Trans Ophthalmol Soc U K* 1983;103 (Pt 4):416-421.
- [5] Schraermeyer U, Heimann K: Current understanding on the role of retinal pigment epithelium and its pigmentation. *Pigment Cell Res* 1999;12:219-236.
- [6] Schraermeyer U, Heimann K: Current understanding on the role of retinal pigment epithelium and its pigmentation. *Pigment Cell Res* 1999;12:219-236.
- [7] Gordon WC, Rodriguez de Turco EB, Bazan NG: Retinal pigment epithelial cells play a central role in the conservation of docosahexaenoic acid by photoreceptor cells after shedding and phagocytosis. *Curr Eye Res* 1992;11:73-83.
- [8] Nilsson SE, Sundelin SP, Wihlmark U, Brunk UT: Aging of cultured retinal pigment epithelial cells: oxidative reactions, lipofuscin formation and blue light damage. *Doc Ophthalmol* 2003;106:13-16.
- [9] Sundelin S, Wihlmark U, Nilsson SE, Brunk UT: Lipofuscin accumulation in cultured retinal pigment epithelial cells reduces their phagocytic capacity. *Curr Eye Res* 1998;17:851-857.
- [10] Katz ML, Gao CL, Rice LM: Formation of lipofuscin-like fluorophores by reaction of retinal with photoreceptor outer segments and liposomes. *Mech Ageing Dev* 20-12-1996;92:159-174.
- [11] Eldred GE: Age pigment structure. *Nature* 29-7-1993;364:396.
- [12] Eldred GE, Lasky MR: Retinal age pigments generated by self-assembling lysosomotropic detergents. *Nature* 25-2-1993;361:724-726.
- [13] Boulton M, McKechnie NM, Breda J, Bayly M, Marshall J: The formation of autofluorescent granules in cultured human RPE. *Invest Ophthalmol Vis Sci* 1989;30:82-89.
- [14] Holz FG, Schutt F, Kopitz J, Eldred GE, Kruse FE, Volcker HE, Cantz M: Inhibition of lysosomal degradative functions in RPE cells by a retinoid component of lipofuscin. *Invest Ophthalmol Vis Sci* 1999;40:737-743.
- [15] Eldred GE, Lasky MR: Retinal age pigments generated by self-assembling lysosomotropic detergents. *Nature* 25-2-1993;361:724-726.
- [16] Delori FC, Dorey CK, Staurengi G, Arend O, Goger DG, Weiter JJ: In vivo fluorescence of the ocular fundus exhibits retinal pigment epithelium lipofuscin characteristics. *Invest Ophthalmol Vis Sci* 1995;36:718-729.
- [17] von RA, Fitzke FW, Bird AC: Distribution of fundus autofluorescence with a scanning laser ophthalmoscope. *Br J Ophthalmol* 1995;79:407-412.
- [18] Bellmann C, Holz FG, Schapp O, Volcker HE, Otto TP: [Topography of fundus autofluorescence with a new confocal scanning laser ophthalmoscope]. *Ophthalmologie* 1997;94:385-391.
- [19] Solbach U, Keilhauer C, Knabben H, Wolf S: Imaging of retinal autofluorescence in patients with age-related macular degeneration. *Retina* 1997;17:385-389.

related macular disease. *Invest Ophthalmol Vis Sci* 2005;46:3309-3314.

- [38] Spaide RF: Fundus autofluorescence and age-related macular degeneration. *Ophthalmology* 2003;110:392-399.

- [20] Delori FC, Staurengi G, Arend O, Dorey CK, Goger DG, Weiter JJ: In vivo measurement of lipofuscin in Stargardt's disease--Fundus flavimaculatus. *Invest Ophthalmol Vis Sci* 1995;36:2327-2331.
- [21] Arend O, Weiter JJ, Goger DG, Delori FC: [In vivo fundus fluorescence measurements in patients with age related macular degeneration]. *Ophthalmologie* 1995;92:647-653.
- [22] Delori FC, Dorey CK: In vivo technique for autofluorescent lipopigments. *Methods Mol Biol* 1998;108:229-243.
- [23] Delori FC, Dorey CK, Staurengi G, Arend O, Goger DG, Weiter JJ: In vivo fluorescence of the ocular fundus exhibits retinal pigment epithelium lipofuscin characteristics. *Invest Ophthalmol Vis Sci* 1995;36:718-729.
- [24] Bellmann C, Holz FG, Schapp O, Volcker HE, Otto TP: [Topography of fundus autofluorescence with a new confocal scanning laser ophthalmoscope]. *Ophthalmologie* 1997;94:385-391.
- [25] Holz FG: [Autofluorescence imaging of the macula]. *Ophthalmologie* 2001;98:10-18.
- [26] Smith RT, Koniarek JP, Chan J, Nagasaki T, Sparrow JR, Langton K: Autofluorescence characteristics of normal foveas and reconstruction of foveal autofluorescence from limited data subsets. *Invest Ophthalmol Vis Sci* 2005;46:2940-2946.
- [27] Holz FG, Bellman C, Staudt S, Schutt F, Volcker HE: Fundus autofluorescence and development of geographic atrophy in age-related macular degeneration. *Invest Ophthalmol Vis Sci* 2001;42:1051-1056.
- [28] Lois N, Halfyard AS, Bird AC, Holder GE, Fitzke FW: Fundus autofluorescence in Stargardt macular dystrophy-fundus flavimaculatus. *Am J Ophthalmol* 2004;138:55-63.
- [29] Lois N, Holder GE, Bunce C, Fitzke FW, Bird AC: Phenotypic subtypes of Stargardt macular dystrophy-fundus flavimaculatus. *Arch Ophthalmol* 2001;119:359-369.
- [30] Lois N, Halfyard AS, Bird AC, Fitzke FW: Quantitative evaluation of fundus autofluorescence imaged "in vivo" in eyes with retinal disease. *Br J Ophthalmol* 2000;84:741-745.
- [31] Lois N, Holder GE, Fitzke FW, Plant C, Bird AC: Intrafamilial variation of phenotype in Stargardt macular dystrophy-Fundus flavimaculatus. *Invest Ophthalmol Vis Sci* 1999;40:2668-2675.
- [32] von RA, Fitzke FW, Bird AC: Fundus autofluorescence in age-related macular disease imaged with a laser scanning ophthalmoscope. *Invest Ophthalmol Vis Sci* 1997;38:478-486.
- [33] Holz FG, Bellmann C, Margaritis M, Schutt F, Otto TP, Volcker HE: Patterns of increased in vivo fundus autofluorescence in the junctional zone of geographic atrophy of the retinal pigment epithelium associated with age-related macular degeneration. *Graefes Arch Clin Exp Ophthalmol* 1999;237:145-152.
- [34] Smith RT, Chan JK, Busuico M, Sivagnanavel V, Bird AC, Chong NV: Autofluorescence characteristics of early, atrophic, and high-risk fellow eyes in age-related macular degeneration. *Invest Ophthalmol Vis Sci* 2006;47:5495-5504.
- [35] Hwang JC, Chan JW, Chang S, Smith RT: Predictive value of fundus autofluorescence for development of geographic atrophy in age-related macular degeneration. *Invest Ophthalmol Vis Sci* 2006;47:2655-2661.
- [36] Schmitz-Valckenberg S, Bindewald-Wittich A, Dolar-Szczasny J, Dreyhaupt J, Wolf S, Scholl HP, Holz FG: Correlation between the area of increased autofluorescence surrounding geographic atrophy and disease progression in patients with AMD. *Invest Ophthalmol Vis Sci* 2006;47:2648-2654.
- [37] Bindewald A, Bird AC, Dandekar SS, Dolar-Szczasny J, Dreyhaupt J, Fitzke FW, Einbock W, Holz FG, Jorzik JJ, Keilhauer C, Lois N, Mlynski J, Pauleikhoff D, Staurengi G, Wolf S: Classification of fundus autofluorescence patterns in early age-